



Summary Feedback

ST1 – ST4 Teaching Programme 2024

Broadcast of Pre-recorded Session

DKT FRCR 2B Practice Viva (Session 84)

DKT Spotlight Series Mastering CT in Acute Abdomen (1/2)

(12th December 2024)

Delivered By:

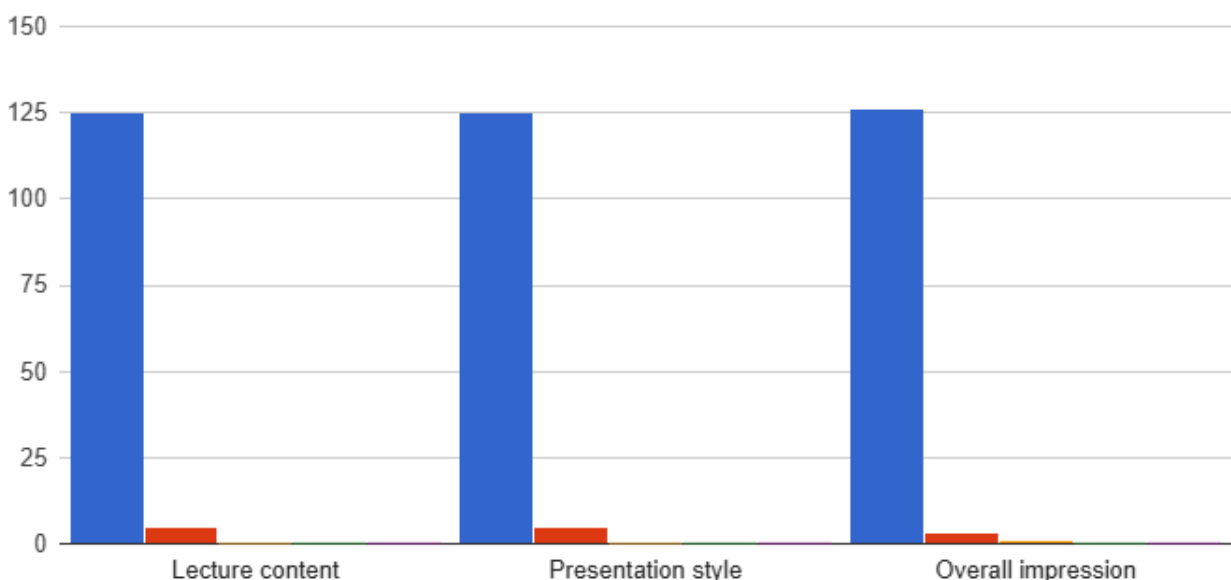
(Sami Khan)

Summary Points:

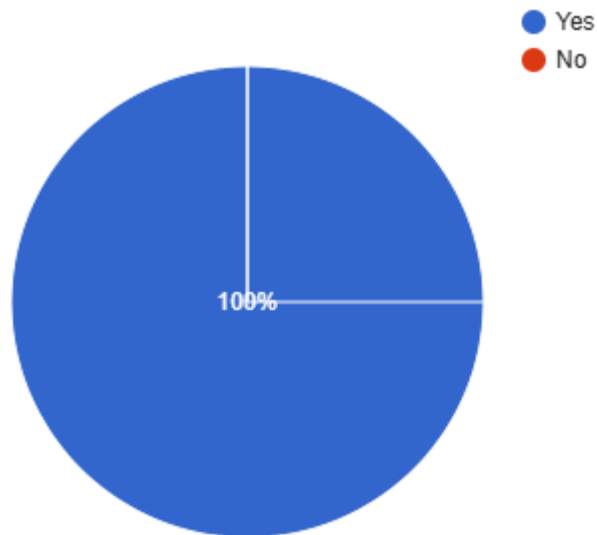
- ST1-ST4 teaching programme 2024 – FRCR 2B Practice Viva Session 84: 2 hours teaching time
- Total Attendees: 372 from 35 Countries (Algeria, Argentina, Australia, Bahrain, Bangladesh, Canada, Dominica, Egypt, Ghana, Hong Kong, India, Indonesia, Iraq, Jordan, Kenya, Kuwait, Libya, Malaysia, Myanmar, Namibia, Nigeria, Oman, Pakistan, Palestine, Poland, Saudi Arabia, South Africa, Sri Lanka, Sudan, Swaziland, Türkiye, UAE, UK, Yemen, Zimbabwe).
- Total feedback received from 130 participants

Please rate the following aspects of the session

Excellent Very good Good Satisfactory Poor



Did you find it useful
130 responses



Testimonials

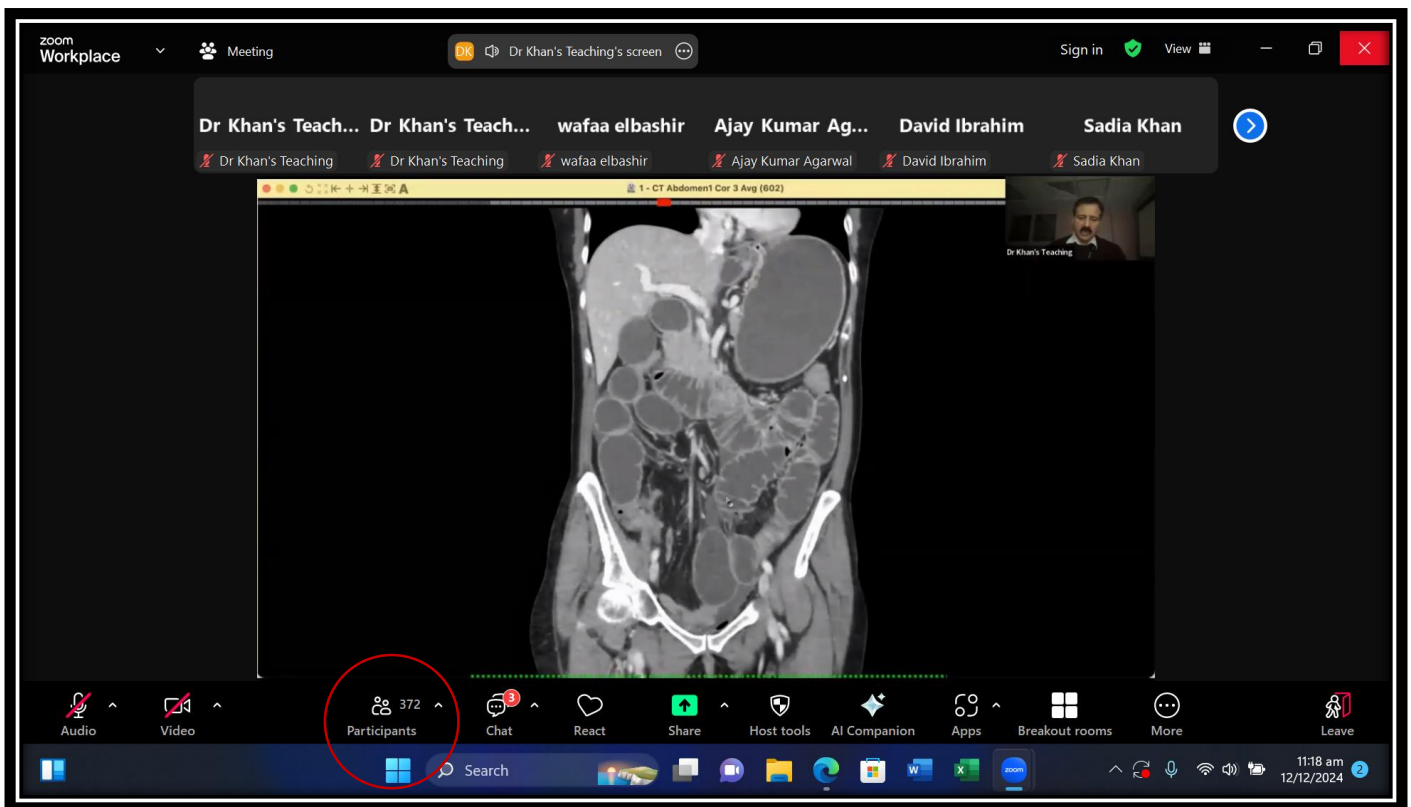
- Thank you, Dr. Khan, for your exceptional acute abdomen in CT. Your clear explanations and in-depth knowledge have greatly enhanced my understanding of this essential topic (Sudan).
- You are our treasure, lots of thanks (Egypt).
- It's perfect as always. You are the best teacher for radiology!!!! (Sri Lanka).
- Very informative and amazing lectures!! thanks a lot (Palestine).
- Nice cases with great teaching points explained by Dr Sami (Pakistan).
- All the session was valuable as it very useful in real life and exam (Sudan).
- Good cases with focus on upcoming exams (UK).
- I am a junior resident but with teachings of Dr Sami getting many things feeling motivated (Pakistan).
- Amazing teaching concepts (India).
- Excellent case collection with clear explanation (UK).
- The patient teaching style was most useful (Nigeria).
- Content and explanation were useful (Sri Lanka).
- Excellent teaching session (Algeria).
- Nice cases lead us to read and improve our knowledge (Yemen).
- Excellent teaching session (Saudi Arabia).
- Very enjoyable and interesting (Sudan).
- I learnt to follow the gut for the first time! Thank you sir (Pakistan).
- Perfect session with Dr. Khan (Sudan).
- It's perfect, thank you so much sir (Egypt).
- Good teachings on acute abdomen CT (Kenya).
- Very educational for day to day practice (UK).
- Outstanding case collection (India).

DKT FRCR 2B Practice Viva (Session 84) - DKT Spotlight Series Mastering CT in Acute Abdomen (1/2)

- Very nicely explained cases (Pakistan).
- It was perfect (UAE).
- The lecture was great (Iraq).
- Interesting cases and constructive feedback (Algeria).
- Approach to case was most useful (Egypt).
- Systematic and thorough coverage of acute abdomen was most useful (Kuwait).
- The images and the discussion of diagnosis were most useful (UK).
- I liked the case based teaching (Sri Lanka).
- How to approach cases was very useful (Bahrain).
- Emergency cases were useful (Egypt).
- The anatomy and tracing of bowel loops were useful (Yemen).
- The cases and the discussion were useful (UK).
- Discussion by Dr Sami was most useful (India).
- Very nice cases of bowel disease interpretation (UAE).
- Cases and discussion were useful (Egypt).
- The cases collection and discussion were useful (Pakistan).
- All the lecture was useful (Saudi Arabia).
- All of it was very useful & highly valuable (Egypt).
- I liked the teaching style and exam related cases (Pakistan).
- Detailed explanation of Rigler's sign and intussusception was useful (Kenya).
- Excellent teaching by Dr. Khan (Pakistan).
- All of it was useful (Iraq).
- Case presentation was most useful (UK).
- Case discussion was useful (India).
- All cases were awesome (Egypt).
- Very nicely sir showed that how to trace bowel (India).
- Focusing on emergency cases was most useful (Egypt).
- Excellent concept building and excellent teaching as always (Pakistan).
- Intra-abdominal fat infarction types were useful (UK).
- The variability of cases was useful (Iraq).
- Variety of cases and in depth discussion was useful (Egypt).
- Well organized (Pakistan).
- All of them were useful (Argentina).
- Brilliant session (Iraq).
- Different presentation of same cases was useful (Pakistan).
- Lot of acute abdomen cases and learned how to diagnose them were most useful (UK).
- Excellent session. Cleared many concepts (Pakistan).
- The technique to check the bowel was most useful (UK).
- All aspects extremely useful (Pakistan).
- Very useful lecture (Libya).
- All of the lecture is useful (Yemen).
- Excellent teaching (UK).
- Great knowledge (Pakistan).
- Perfect (UK).
- Well delivered (Pakistan).
- It was perfect (Iraq).
- Excellent content (UK).
- It was perfect (UAE).
- Very helpful lecture (UK).

DKT FRCR 2B Practice Viva (Session 84) - DKT Spotlight Series Mastering CT in Acute Abdomen (1/2)

- Very informative (UAE).
- Perfect (Saudi Arabia).
- Excellent informative session (Pakistan).
- Excellent (UK).
- Remarkable session (India).
- Woow (Egypt).
- Brilliant (UK).
- Very informative (Nigeria).
- Wonderful session (Pakistan).
- Best (Pakistan).
- Excellent session (UK).
- Brilliant session (Pakistan).
- Excellent teaching session (Nigeria).
- Good lecture (UK).


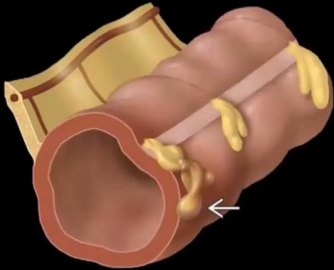


DKT FRCR 2B Practice Viva (Session 84) - DKT Spotlight Series Mastering CT in Acute Abdomen (1/2)

zoom Workplace Meeting Dr Khan's Teaching's screen Sign in View

Dr Khan's Teach... Dr Khan's Teach... wafaa elbashir Ajay Kumar Ag... David Ibrahim Sadia Khan

Epiploic Appendagitis



STAT

Different cases 3/3


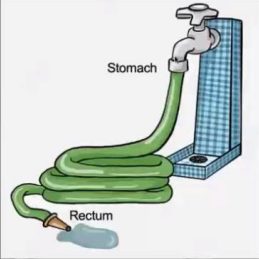
Audio Video Participants 357 Chat React Share Host tools AI Companion Apps Breakout rooms More Leave

11:58 am 12/12/2024

zoom Workplace Meeting Dr Khan's Teaching's screen Sign in View

Dr Khan's Teach... Dr Khan's Teach... wafaa elbashir Ajay Kumar Ag... David Ibrahim Sadia Khan

How to Report CT Abdomen ? : Gut



Stomach

Rectum

Follow from top to bottom & / or from bottom to top

Audio Video Participants 291 Chat React Share Host tools AI Companion Apps Breakout rooms More Leave

10:40 am 12/12/2024

====XX====XX=====